CASE REPORT

Management of enteroatmospheric fistula thanks to new isolation technique

Seracettin Eğin, M.D., Berk Gökçek, M.D., Metin Yeşiltas, M.D., Fazıl Sağlam, M.D., Burak Güney M.D.

Department of General Surgery, University of Health Sciences, Okmeydanı Training and Research Hospital, İstanbul-*Turkey*

ABSTRACT

We aimed to present our method called as new isolation technique with stopper (NITS) to manage enteroatmospheric fistula (EAF) in an open abdomen (OA). The patient was a 71-year-old male with Hartmann colostomy and incisional hernia. A dual mesh was used for incisional hernia repair after colorectal anastomosis. The patient was urgently re-admitted to hospital due to EAF on the postoperative 30th day. The NITS application was performed twice at different times. General anesthesia was not required for the applications, but sterile conditions in operation room were provided. A Penrose drain was sutured with 5/0 polydioxanone onto the mucosa of EAF orifice. A small pool was created to protect enteric content from leakage. The leak test was performed by spilling saline into this pool. The sponge with visceral organ protector around the pool was adhered by adhesive sterile drape, and one opening was performed on drape. Negative pressure therapy was launched with -75 mmHg in continuous form. EAF was isolated from the OA wound and sponge with the help of stopper performed with adaptable and obstacle ring paste. After these two applications, EAF was converted to stoma. The anastomosis of small intestine was performed 45 days later. In our NITS system, control of EAF may be successfully provided besides prevention of loss of enteric fluid and electrolyte. Advantages of NITS: 1) Successful control in all types of EAF is possible with NITS. 2) The required material for NITS system can be found easily. 3) All types of EAF can be converted into stoma in a short time. Consequently, the therapy of EAF in Björck 4 OA patients may be carried out successfully with NITS method.

Keywords: Enteroatmospheric fistula; negative pressure therapy; open abdomen; penrose drain.

INTRODUCTION

The enteroatmospheric fistula (EAF) has been described as a fistula that directly opens the gastrointestinal tract to the atmosphere without any canal.[1,2] Open abdomen (OA) practice provides the survival in cases such as severe generalized peritonitis, severe pancreatitis, abdominal aortic aneurysm rupture, acute mesenteric ischemia, damage-control surgery after trauma, and abdominal compartment syndrome, but its application is a challenging strategy. EAF in an OA is a feared complication that can cause death. If EAF takes place, therapy of the patients with OA gets harder, and the likelihood of mortality and morbidity also increases.[1] The identified treatment methods for EAF are biological dressings, vacuum-assisted closure (VAC), application of fibrin glue, sump drainage, primary suturing, and fistula VAC technique. It is essential to control the enteric effluent of EAF. The uncontrolled flow of EAF makes it difficult to heal the wound with irritation of the surrounding skin due to persistent contamination.[2] EAF associated with frozen OA is classified as Björck 4 OA.[1] It may not always be possible to prevent persistent contamination and chemical irritation caused by EAF in the patients with Björck 4 OA. If the isolation of the EAF is not fully achieved in these patients, their death is usually the clear outcome due to sepsis.

This case report describes our experience with negative pressure therapy (NPT) in the management of EAF in an OA.

Cite this article as: Eğin S, Gökçek B, Yeşiltas M, Sağlam F, Güney B. Management of enteroatmospheric fistula thanks to new isolation technique. Ulus Travma Acil Cerrahi Derg 2019;25:80-82.

Address for correspondence: Seracettin Eğin, M.D.
Sağlık Bilimleri Üniversitesi, Okmeydanı Eğitim ve Araştırma Hastanesi, Genel Cerrahi Kliniği, İstanbul, Turkey.
Tel: +90 212 - 314 55 55 E-mail: seracettin_egin@hotmail.com

Ulus Travma Acil Cerrahi Derg 2019;25(1):80-82 DOI: 10.5505/tjtes.2018.45267 Submitted: 11.11.2018 Accepted: 17.12.2018 Online: 25.12.2018
Copyright 2019 Turkish Association of Trauma and Emergency Surgery

We aimed to present our method called as new isolation technique with stopper (NITS), performed by modifying "fistula isolation by suturing the Penrose drain to the mucosa of orifice of EAF" (FISPME) method. In a short time, condition of our patient with EAF in Björck 4 OA improved thanks to this method without excessive fluid losses, electrolyte and acid-base disturbances, and septic complications.

CASE REPORT

The patient, a 71-year-old male, was operated 13 months after his first surgery for the closure of the previous Hartmann colostomy and incisional hernia. A dual mesh was used for incisional hernia repair after colorectal anastomosis. After discharge, the patient was urgently re-admitted to hospital due to EAF 30 days after surgery (Fig. 1a). Informed consent was obtained from the patient, and he was operated 32 days after surgery for the first NITS application. The application was performed twice at different times. The second NITS was performed 55 days after surgery. The second NITS was performed when the first NITS broke down. General anesthesia was not required for the applications, but sterile conditions in operation room were provided. A Penrose drain was sutured with 5/0 polydioxanone onto the mucosa of EAF orifice (Fig. 1b). A small volume pool was created by suturing the Penrose drain to avoid leakage of enteric content. The leak test was performed by spilling saline into this pool. A pool area was created on the sponge of NPT. The sponge with visceral organ protector around the pool was applied according to OA wound, and sutured to the top edge of Penrose. A small dry gauze was placed in this pool. The gauze in this pool and the sponge with visceral organ protector around of the pool was adhered by adhesive sterile drape, and one opening was performed on drape. The collecting system channel of NPT was affixed to this opening. NPT was launched with −75 mmHg in continuous form. The drape on this pool was opened by

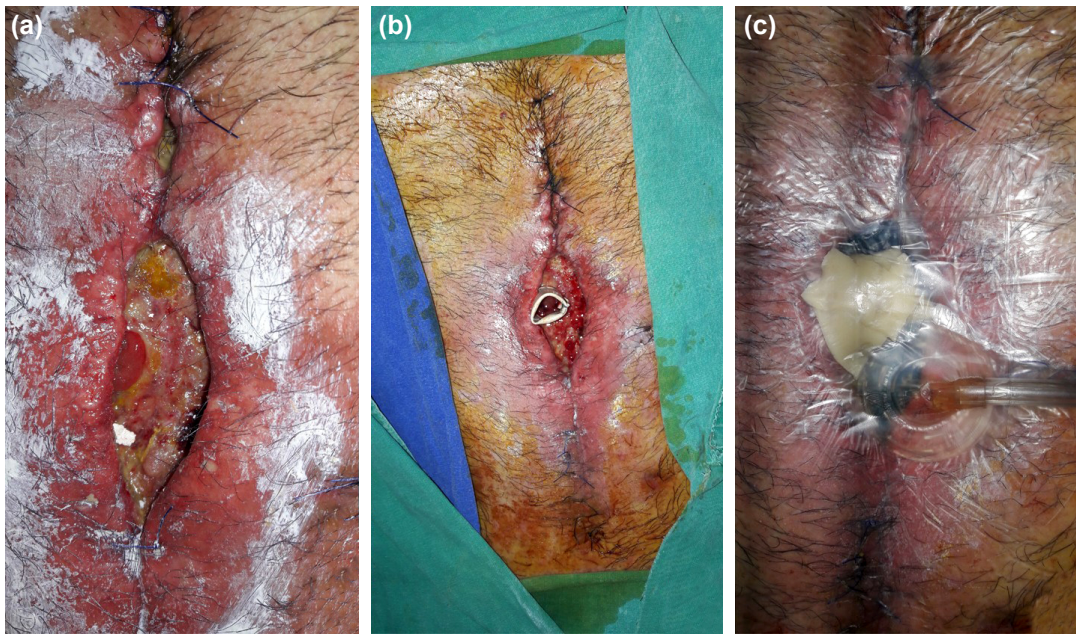

Figure 1. (a) EAF at the small intestine. **(b)** A Penrose drain was sutured with 5/0 polydioxanone onto the mucosa of EAF orifice. **(c)** EAF was isolated from the OA wound and sponge with the help of stopper performed with adaptable and obstacle ring paste.

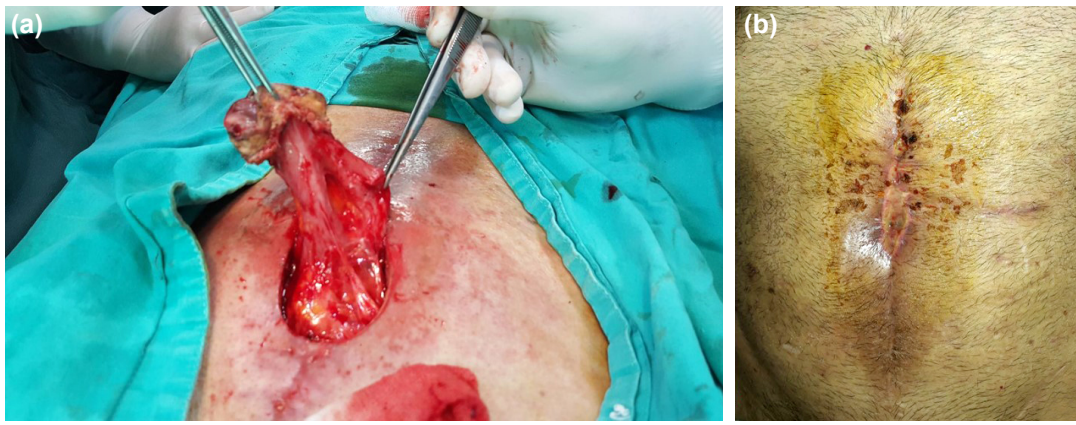

Figure 2. (a) Releasing the afferent and efferent small intestine loops of the stoma. **(b)** The patient fully recovered.

cutting, and the gauze was removed. EAF was isolated from the OA wound and sponge with the help of stopper performed with adaptable and obstacle ring paste (Fig. 1c). After these two applications, EAF was converted to stoma 58 days after surgery. Stoma bag was applied to enterostomy, and the patient was discharged 75 days after surgery. After 58 days of discharge, side-to-side anastomosis was performed with the linear cutter by releasing the afferent and efferent small intestine loops of the stoma (Fig. 2a). The patient was discharged 12 days after last surgery as fully recovered (Fig. 2b).

DISCUSSION

When NPT was introduced, some considered the usage of vacuum therapy for fistula improvement a contraindication. However, nowadays the use of NPT has been reported in several case report and case series with excellent results.[3] In 2017, Yetisir et al.[4] described an innovative technique called FISPME that is applied with VAC to treat EAF in Björck 4 OA patients. Our technique is a modification of the technique described by Yetisir et al., but there are significant differences in both application technique and post-application nutrition. Because we isolated EAF with stopper, a stoma bag did not need to stick around the EAF orifice. Thus, there was no loss of excess fluid and electrolyte from EAF. The patients with EAF are hypercatabolic, and their health rapidly deteriorate. Nutritional support for these patients is an important predictor for survival. We preferred total parenteral nutrition support for short time although enteral nutrition was preferred by Yetisir et al.

In Björck 4 OA patients, proximal diversion of enteric contents is not possible. However, isolation techniques of the enteric contents are possible for control of the EAF in these patients. These techniques were described by D'Hondt and Jannasch in 2011.[3,5] Afterwards, some techniques such as floating stoma, fistula VAC, tube VAC, nipple VAC, ring and silo VAC were described by Marinis et al.[2] in 2013. Applications of these techniques are not easy for EAF. The leak from EAF to surface of the OA wound is an important problem for all these EAF control systems. The leak always occurs because isolation of the enteric contents may not be successfully performed. These control systems fail every time.

In our NITS system, control of EAF may be successfully provided besides prevention of loss of enteric fluid and electrolyte. Advantages of NITS: 1) Successful control in all types of EAF is possible with NITS. 2) The required material for NITS system can be found easily. 3) All types of EAF can be converted into stoma in a short time. Consequently, the therapy of EAF in Björck 4 OA patients may be carried out successfully with NITS method.

Conflict of interest: None declared.

REFERENCES

1. Kirkpatrick AW, Roberts DJ, De Waele J, Jaeschke R, Malbrain ML, De Keulenaer B, et al; Pediatric Guidelines Sub-Committee for the World Society of the Abdominal Compartment Syndrome. Intra-abdominal hypertension and the abdominal compartment syndrome: updated consensus definitions and clinical practice guidelines from the World Society of the Abdominal Compartment Syndrome. Intensive Care Med 2013;39:1190–206. [CrossRef]
2. Marinis A, Gkiokas G, Argyra E, Fragulidis G, Polymeneas G, Voros D. "Enteroatmospheric fistulae"--gastrointestinal openings in the open abdomen: a review and recent proposal of a surgical technique. Scand J Surg 2013;102:61–8. [CrossRef]
3. D'Hondt M, Devriendt D, Van Rooy F, Vansteenkiste F, D'Hoore A, Penninckx F, et al. Treatment of small-bowel fistulae in the open abdomen with topical negative-pressure therapy. Am J Surg 2011;202:e20–4.
4. Yetisir F, Sarer AE, Aldan M. New isolation technique for enteroatmospheric fistula in Björck 4 open abdomen. Hernia 2017;21:809–12.
5. Jannasch O, Lippert H, Tautenhahn J. A novel device for treating enteroatmospheric fistulae in the open abdomen. [Article in German]. Zentralbl Chir 2011;136:585–9. [CrossRef]

OLGU SUNUMU - *ÖZET*

Yeni izolasyon tekniği ile enteroatmosferik fistülün yönetimi

Dr. Seracettin Eğin, Dr. Berk Gökçek, Dr. Metin Yeşiltas, Dr. Fazıl Sağlam, Dr. Burak Güney

Sağlık Bilimleri Üniversitesi, Okmeydanı Eğitim ve Araştırma Hastanesi, Genel Cerrahi Kliniği, İstanbul

Açık karında enteroatmosferik fistül (EAF) yönetiminde tıkaçla yeni izolasyon tekniği olarak adlandırılan yöntemimizi sunmayı amaçladık. Hasta, Hartmann kolostomi ve insizyonel herni olan 71 yaşında bir erkek hastaydı. Kolorektal anastomoz sonrası insizyonel fıtık onarımı için dual meç kullanıldı. Hasta, acil olarak EAF nedeniyle ameliyat sonrası otuzuncu günde hastaneye tekrar başvurdu. Yeni izolasyon tekniği uygulaması iki kez farklı zamanlarda yapıldı. Genel anestezi gerekli değildi, ancak ameliyat odasında steril koşullar sağlandı. Bir penroz dren, 5/0 polidioksanon ile EAF mukozasına dikildi. Enterik içeriği sızdırmayan küçük bir havuz oluşturuldu. Sızıntı testi, bu havuza serum fizyolojik dökülerek yapıldı. Havuzun etrafındaki açık karın alanı organ koruyuculu süngerle ve steril dreple örtüldü. Örtü üzerinde bir açıklık yapıldı ve sürekli formda -75 mmHg ile negatif basınç tedavisi başlatıldı. EAF, açık karın yarasından ve süngerden, el ile şekil verilebilen ve sızdırmaz halka macunu ile yapılan tıkaç yardımıyla izole edildi. Bu iki uygulamadan sonra, EAF stomaya dönüştürüldü. İnce bağırsağın anastomozu 45 gün sonra yapıldı. Tıkaçla yeni izolasyon tekniği sistemimizde, enterik sıvı ve elektrolit kaybını önlemenin yanı sıra EAF'nin kontrolü de sağlanabilir. Tıkaçla yeni izolasyon tekniğinin üstünlükleri: 1. Her türlü EAF'de başarılı kontrol mümkün olabilir. 2. Sistemimiz için gerekli materyal kolayca bulunabilir. 3. Tüm EAF tipleri kısa sürede stomaya dönüştürülebilir. Sonuç olarak, Björck 4 açık karın hastalarında EAF tedavisi tıkaçla yeni izolasyon tekniğiyle başarılı şekilde gerçekleştirilebilir.

Anahtar sözcükler: Açık karın; enteroatmosferik fistül; negatif basınç tedavisi; penroz dren.

Ulus Travma Acil Cerrahi Derg 2019;25(1):80-82 doi: 10.5505/tjtes.2018.45267